Open Access Article

Ann. Acad. Med. Siles. (Online) 2026;80:433–438
eISSN 1734-025X
DOI: 10.18794/aams/219124
www.annales.sum.edu.pl

OPIS PRZYPADKU
CASE REPORT

Choroidal rupture after blunt ocular trauma in a 21-year-old patient: A case report

Pęknięcie naczyniówki po tępym urazie gałki ocznej u 21-letniej pacjentki – opis przypadku

Natalia Kwaśniewska[1], Przemysław Ciszewski[1], Sebastian Sirek[2,3], Dorota Wyględowska-Promieńska[2,3]

[1]Students' Scientific Club, Department of Ophthalmology, Faculty of Medical Sciences in Katowice, Medical University of Silesia, Katowice, Poland

[2]Department of Ophthalmology, Faculty of Medical Sciences in Katowice, Medical University of Silesia, Katowice, Poland

[3]Department of Adult Ophthalmology, Prof. K. Gibinski University Clinical Center, Medical University of Silesia, Katowice, Poland

ABSTRACT

A choroidal rupture (CR) is a disruption of the continuity of the choroid, Bruch's membrane and the retinal pigment epithelium; it is most commonly associated with blunt ocular trauma. It occurs in 5%–10% of patients after globe injury, and more frequently in young men and during work-related activities or physical exercise. A 21-year-old female patient presented to the Ophthalmic Emergency Department after sustaining blunt trauma to the left eye caused by being struck with a mobile phone. On admission, best-corrected visual acuity (BCVA) was 0.01 and intraocular pressure (IOP) was 39 mmHg. Ophthalmic examination revealed subluxation of the crystalline lens, prolapse of the vitreous body into the anterior chamber and a CR. Flash visual evoked potentials showed normal latencies. However, the amplitude in the left eye was reduced to 50%. Fundus examination of the left eye revealed a rupture with displacement of the vascular bundle, signs of fibrosis, retinal haemorrhages, CR, post-haemorrhagic vitreous opacities and macular oedema. Fluorescein angiography revealed preserved flow in the major vessels, an area of hypo- and hyperfluorescence in the peripapillary region and scattered foci of blocked fluorescence inferiorly corresponding to dispersed haemorrhages. Based on the clinical presentation and ancillary test results, systemic and topical treatment was initiated, resulting in clinical improvement. BCVA remained at 0.01, while IOP decreased to 16 mmHg following pharmacological therapy. Post-traumatic CR frequently coexists with other ocular structural injuries. It requires comprehensive diagnostic evaluation and management, and the prognosis depends on the location and extent of the lesions as well as appropriately selected pharmacotherapy.

KEYWORDS

ocular trauma, lens subluxation, choroidal rupture

Received: 18.01.2026 **Revised:** 06.02.2026 **Accepted:** 10.03.2026 **Post-print published:** 12.05.2026 **Final published:** 27.11.2026

Address for correspondence: Natalia Kwaśniewska, Studenckie Koło Naukowe, Klinika Okulistyki, ul. Ceglana 35, 40-514 Katowice, tel. +48 32 358 12 27, e-mail: s85936@365.sum.edu.pl

This is an open access article made available under the terms of the Creative Commons Attribution-ShareAlike 4.0 International (CC BY-SA 4.0) license, which defines the rules for its use. It is allowed to copy, alter, distribute and present the work for any purpose, even commercially, provided that appropriate credit is given to the author and that the user indicates whether the publication has been modified, and when processing or creating based on the work, you must share your work under the same license as the original. The full terms of this license are available at https://creativecommons.org/licenses/by-sa/4.0/legalcode.

© Copyright by Author(s)

Publisher: Medical University of Silesia, Katowice, Poland

STRESZCZENIE

Pęknięcie naczyniówki (*choroidal rupture* – CR) to przerwanie ciągłości błony naczyniowej, błony Brucha i nabłonka barwnikowego siatkówki, najczęściej towarzyszące tępym urazom oka. Występuje u 5–10% pacjentów po urazie gałki ocznej; częściej dotyczy młodych mężczyzn i może wystąpić podczas pracy lub wysiłku fizycznego. Pacjentka, 21-letnia, zgłosiła się do Okulistycznej Izby Przyjęć z powodu tępego urazu oka lewego w wyniku uderzenia telefonem. Najlepsza skorygowana ostrość wzroku (*best-corrected visual acuity* – BCVA) przy przyjęciu wynosiła 0,01, a ciśnienie wewnątrzgałkowe (*intraocular pressure* – IOP) było na poziomie 39 mmHg. W badaniu okulistycznym stwierdzono podwichnięcie soczewki własnej, przepuklinę ciała szklistego do komory przedniej oraz CR. Wzrokowe potencjały wywołane błyskiem wykazały prawidłowe latencje, jednak amplituda w oku lewym była obniżona do 50%. W badaniu dna oka lewego stwierdzono pęknięcie z przemieszczeniem pęczka naczyniowego, cechy włóknienia, krwotoki siatkówkowe, CR, męty pokrwotoczne oraz obrzęk plamki. Angiografia fluoresceinowa wykazała zachowany przepływ w głównych naczyniach, obszary hipo- i hiperfluorescencji w okolicy okołotarczowej oraz rozproszone ogniska blokady fluorescencji w dolnej części dna oka, w miejscu rozsianych krwotoków. Na podstawie obrazu klinicznego i wyników badań dodatkowych wdrożono leczenie ogólne i miejscowe, co przyniosło poprawę stanu klinicznego. BCVA pozostała na poziomie 0,01, natomiast IOP po zastosowaniu farmakoterapii obniżyło się do 16 mmHg. CR po urazie często współistnieje z innymi uszkodzeniami struktur oka. Wymaga ono kompleksowej diagnostyki i leczenia, a rokowanie zależy od lokalizacji, rozległości zmian oraz odpowiedniej farmakoterapii.

SŁOWA KLUCZOWE

uraz oka, podwichnięcie soczewki, pęknięcie naczyniówki

INTRODUCTION

Choroidal rupture (CR) was first described by von Graefe in 1854 in patients with blunt ocular trauma. It is defined as a disruption of the choroid, Bruch's membrane and the retinal pigment epithelium (RPE). Ruptures may be classified as direct (coup injury) or indirect (countercoup injury). Direct ruptures occur at the site of impact, typically parallel to the ora serrata and the peripheral retina. In contrast, indirect ruptures occur at a site distant from the impact, usually at the posterior pole, where they assume a crescent shape arranged concentrically around the optic disc. Approximately 80% of CRs are indirect [1].

CR occurs in about 5%–10% of patients with globe trauma and is three times more common in closed--globe injuries than in open-globe injuries [2]. During trauma, the globe undergoes rapid mechanical deformation. The sclera, composed mainly of connective tissue, provides structural strength and relative resistance to injury. The retina is elastic and capable of stretching, whereas the RPE–Bruch's membrane–choroid complex has limited elasticity and tensile strength, making it susceptible to rupture. This disruption damages choroidal capillaries and results in bleeding into the subretinal space [3].

Sports injuries, physical assaults and occupational accidents are the most common causes of CR, which explains its higher prevalence among young men. Patients with angioid streaks are at increased risk due to the fragility of Bruch's membrane [4]. CR may also occur during forceps-assisted delivery or as a complication of intravitreal anti-vascular endothelial growth factor (anti-VEGF) injections used in the treatment of retinopathy of prematurity [2].

This report presents the case of a young female patient who developed CR with lens subluxation following blunt ocular trauma.

CASE REPORT

A 21-year-old female presented to the Ophthalmic Emergency Department after sustaining blunt trauma to the left eye when struck with a mobile phone during an altercation with a friend. The patient was otherwise healthy and reported no relevant comorbidities. On admission, best-corrected visual acuity (BCVA) in the left eye was 0.01, and intraocular pressure (IOP) measured 39 mmHg. Ophthalmic examination revealed subluxation of the crystalline lens, prolapse of the vitreous body through the pupillary margin into the anterior chamber and CR.

Fundus examination demonstrated a rupture with displacement of the vascular bundle, fibrotic changes, retinal haemorrhages, post-haemorrhagic vitreous opacities, macular oedema, reduced perfusion in the inferior quadrant and interrupted retinal vessels (Figure 1). Macular oedema was also present on the optical coherence tomography (Figure 2).

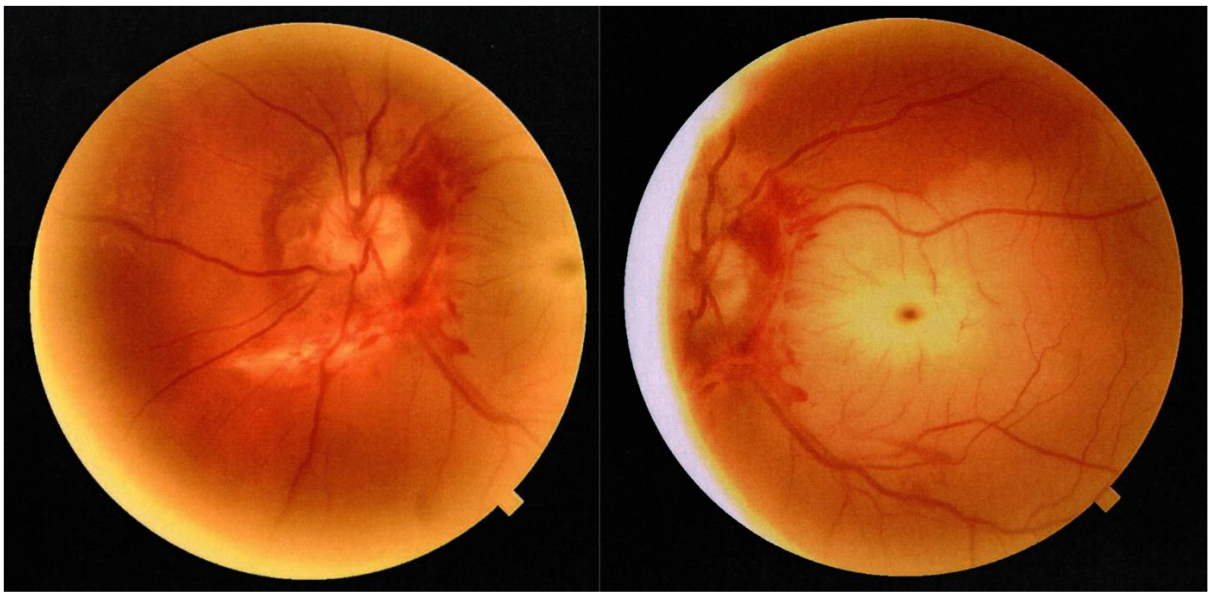

Fig. 1. Fundus photograph of the left eye

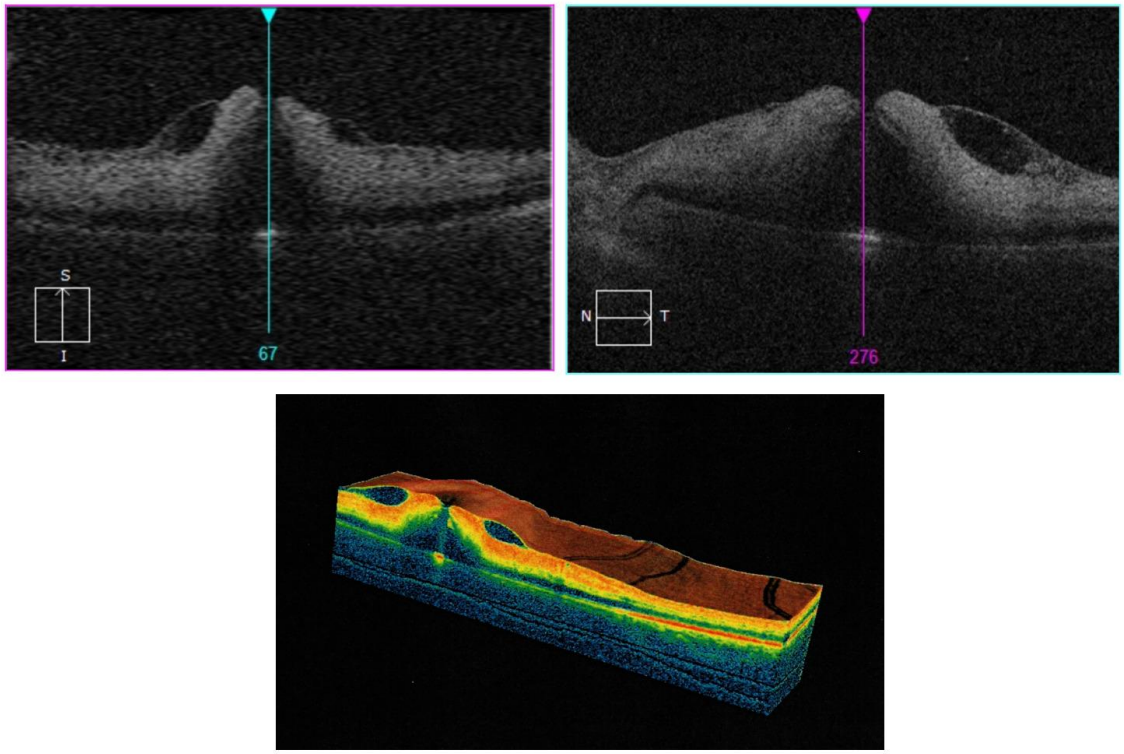

Fig. 2. Optical coherence tomography of the left eye: different planes

Flash visual evoked potentials showed normal latency; however, the amplitude in the left eye was reduced to 50% compared with the right eye. Fluorescein angiography demonstrated preserved flow through the major vessels. Visualisation of the fundus was slightly hazy. A peripapillary area of hypo- and hyperfluorescence suggested oedema, while scattered inferior foci of blocked fluorescence corresponded to dispersed retinal haemorrhages (Figure 3).

Based on the clinical findings and ancillary test results, combined systemic and topical treatment was initiated, resulting in gradual clinical improvement. Systemic therapy included acetazolamide, methylprednisolone (2 mg) and supplementation with magnesium and potassium. Topical therapy consisted of latanoprost once daily, bromfenac three times daily, a fixed combination of dorzolamide and timolol, tropicamide twice daily and fluorometholone three times daily.

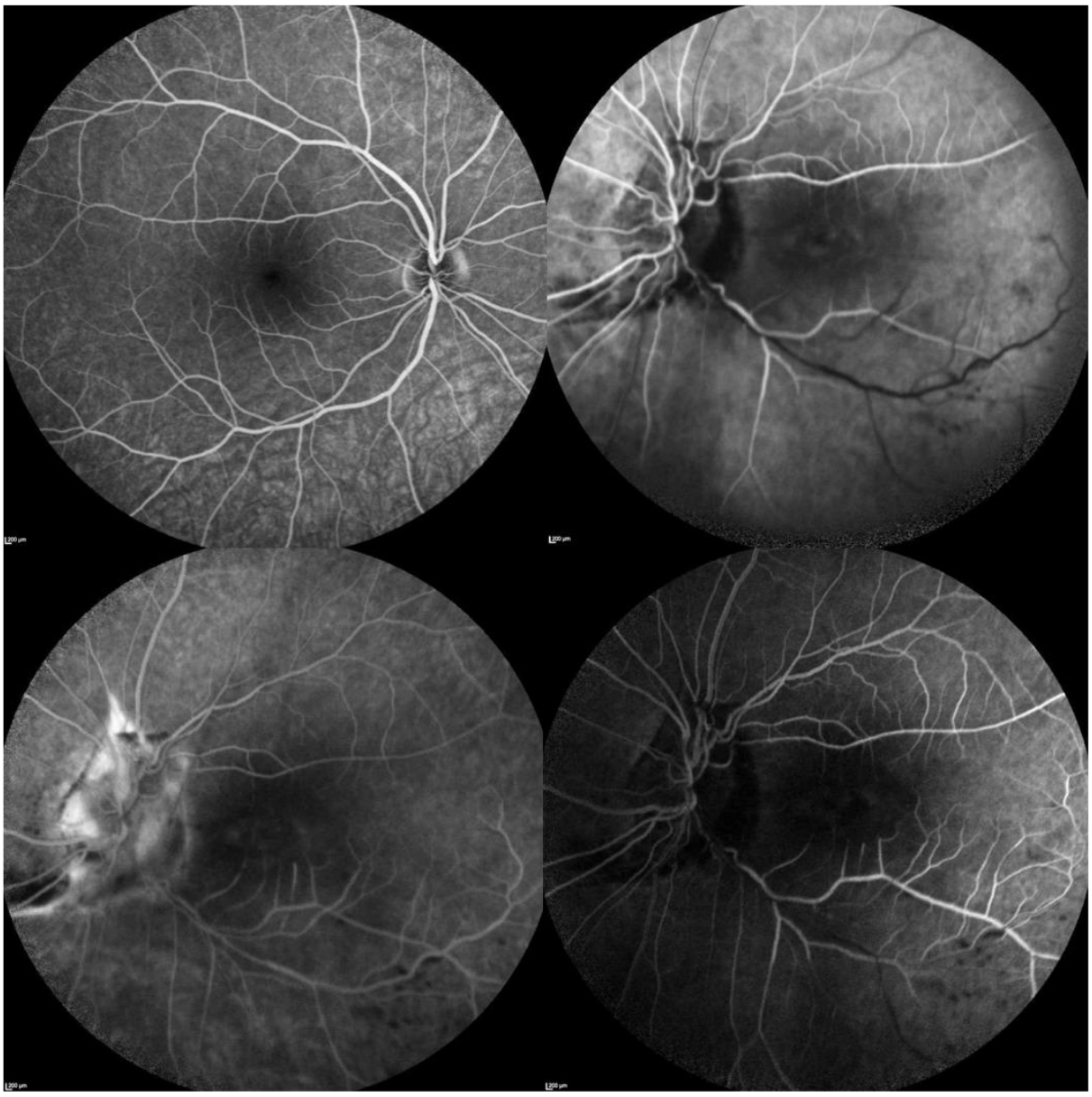

Fig. 3. Fluorescein angiography of the left eye

At a follow-up visit 3 weeks later, BCVA remained at 0.01, while IOP had normalised to 16 mmHg. Ophthalmic examination revealed persistent vitreous prolapse, iridodonesis, inferior pigment dispersion within the vitreous, a pigment granule at the 10-o'clock position on the iris margin and continued lens subluxation.

Topical treatment with bromfenac, fluorometholone and tropicamide was continued, along with systemic acetazolamide and electrolyte supplementation. Other medications were discontinued, and another follow-up visit was scheduled for 1 month later.

DISCUSSION

CR is a complex complication of blunt ocular trauma that requires careful evaluation to guide appropriate management. Visual impairment most commonly results from secondary choroidal neovascularization (CNV) [2]. In this case, the patient developed acute mechanical complications, including subretinal haemorrhage and macular oedema, with no evidence of CNV. Therefore, a conservative approach to macular management was adopted, as anti-VEGF therapy is

reserved for cases with confirmed neovascular activity [5].

The main clinical challenge in this patient was the significant elevation of IOP (39 mmHg). This was most likely caused by mechanical disruption of the lens–iris complex following trauma, resulting in lens subluxation and vitreous prolapse. Such disturbances often lead to iridodonesis and pigment dispersion within the anterior chamber, a well-recognised mechanism that contributes to secondary traumatic glaucoma in young adults [6,7].

Despite reduced fundus visibility and the presence of multi-level ocular trauma, visual evoked potential testing provided valuable prognostic information. The observed electrophysiological pattern – reduced amplitude with preserved latency – may indicate partial traumatic optic nerve involvement while suggesting potential for functional recovery [8]. As there was no evidence of optic canal fracture or complete loss of light perception, surgical optic nerve decompression was not indicated [9]. Nevertheless, early pharmacological treatment remains important to limit neurodegenerative changes associated with traumatic optic neuropathy [10].

The topical and systemic treatment regimen was therefore tailored to address the patient's acute clinical presentation. Acetazolamide, beta-blockers and prostaglandin analogues were administered to rapidly reduce IOP and prevent glaucomatous damage [7,11]. Corticosteroids and non-steroidal anti-inflammatory drugs were used concurrently to control post-traumatic inflammation and to stabilise the disrupted blood––ocular barrier [11].

Significant lens displacement and vitreous prolapse may require surgical intervention, including pars plana vitrectomy and lensectomy [3,12]. In this case, however, surgery was postponed. The immediate priority was medical stabilisation of the IOP and inflammation. Surgical reconstruction may be considered after the acute haemorrhagic and oedematous phase is resolved, which reduces the risk of intraoperative complications [12].

Management of CR itself typically involves observation. Anti-VEGF therapy is primarily indicated when CNV develops [5]. Visual prognosis largely depends on lesion location. Ruptures involving the fovea are associated with poorer outcomes and a higher risk of CNV. Additional unfavourable prognostic factors include extensive injury involving the optic disc, macular holes, optic atrophy or pronounced pigmentary changes [2]. CNV develops in approximately 7.9% of CR cases, most frequently in lesions involving the fovea [13].

Intravitreal anti-VEGF therapy has proven safe and effective for CNV secondary to choroidal rupture, resulting in lesion regression and visual improvement. In a retrospective study with a mean follow-up of 5 years, these outcomes were achieved with an average of 4.2 injections per eye, while 40% of patients required only a single injection. All treated patients achieved regression of neovascularisation, and most experienced visual improvement. Compared with neovascular age-related macular degeneration, post-traumatic CNV typically requires fewer injections but still necessitates long-term follow-up because of the risk of late recurrence [5].

Earlier therapeutic approaches included laser photocoagulation and photodynamic therapy (PDT). Argon laser photocoagulation was limited to extrafoveal lesions and did not significantly improve long-term visual outcomes. PDT enabled subfoveal lesions to be treated and provided partial visual stabilisation in some cases, although its effectiveness was often limited and temporary [2].

In our patient, fluorescein angiography showed no evidence of active neovascularisation, supporting an observational strategy. However, isolated reports have described the use of intravitreal bevacizumab in traumatic CR without CNV, resulting in faster resolution of subretinal fluid and improved visual outcomes [14].

CONCLUSIONS

In this case, early monitoring and prompt control of post-traumatic complications preserved visual function despite a complex posterior segment injury. Individualised management that considers the location of the CR, lens stability and the risk of neovascularisation is essential for optimising patient outcomes.

This study was conducted in accordance with the Code of Ethics of the World Medical Association (Declaration of Helsinki).

Conflict of interest

The authors declare that there is no conflict of interest.

Use of AI tools statement

ChatGPT was used to translate the manuscript.

Authors' contribution

Study design – N. Kwaśniewska, D. Wyględowska-Promieńska, S. Sirek, P. Ciszewski
Manuscript preparation – N. Kwaśniewska, S. Sirek, P. Ciszewski
Literature research – N. Kwaśniewska, P. Ciszewski
Final approval of the version to be published – D. Wyględowska-Promieńska, S. Sirek

REFERENCES

1. Singh S, Saxena S. Unraveling the perplexities of choroidal rupture. Indian J Ophthalmol. 2023;71(6):2602–2603. doi: 10.4103/IJO.IJO_326_23.
2. Lupidi M, Muzi A, Castellucci G, Kalra G, Piccolino FC, Chhablani J, et al. The choroidal rupture: current concepts and insights. Surv Ophthalmol. 2021;66(5):761–770. doi: 10.1016/j.survophthal.2021.01.014.
3. Mohseni M, Blair K, Gurnani B, Bragg BN. Blunt Eye Trauma. 2023 Jun 11. In: StatPearls [Internet]. Treasure Island (FL): StatPearls Publishing; 2025 Jan–.
4. Patel MM, Chee YE, Eliott D. Choroidal rupture: a review. Int Ophthalmol Clin 2013;53(4):69–78. doi: 10.1097/IIO.0b013e31829ced74.
5. Barth T, Zeman F, Helbig H, Gamulescu MA. Intravitreal anti-VEGF treatment for choroidal neovascularization secondary to traumatic choroidal rupture. BMC Ophthalmol. 2019;19(1):239. doi: 10.1186/s12886-019-1242-7.
6. Razeghinejad R, Lin MM, Lee D, Katz LJ, Myers JS. Pathophysiology and management of glaucoma and ocular hypertension related to trauma. Surv Ophthalmol. 2020;65(5):530–547. doi: 10.1016/j.survophthal.2020.02.003.
7. Ng JK, Lau O. Traumatic Glaucoma. 2023 Aug 14. In: StatPearls [Internet]. Treasure Island (FL): StatPearls Publishing; 2025 Jan–.
8. Tabatabaei SA, Soleimani M, Alizadeh M, Movasat M, Mansoori MR, Alami Z, et al. Predictive value of visual evoked potentials, relative afferent pupillary defect, and orbital fractures in patients with traumatic optic neuropathy. Clin Ophthalmol. 2011;5:1021–1026. doi: 10.2147/OPTH.S21409.
9. He M, Yang Z, Shi Z, Chen Y, Zhao X. Clinical features, management, and prognosis factors of traumatic optic neuropathy. Surv Ophthalmol. 2026;71(1):168–178. doi: 10.1016/j.survophthal.2025.07.012.
10. Blanch RJ, Joseph IJ, Cockerham K. Traumatic optic neuropathy management: a systematic review. Eye (Lond). 2024;38(12):2312–2318. doi: 10.1038/s41433-024-03129-7.
11. Weinreb RN, Aung T, Medeiros FA. The pathophysiology and treatment of glaucoma: a review. JAMA. 2014;311(18):1901–1911. doi: 10.1001/jama.2014.3192.
12. Hapca MC, Muntean GA, Nemeș-Drăgan IA, Vesa ȘC, Nicoară SD. Visual Outcomes of Traumatic Lens Dislocations and Subluxations Managed by Pars Plana Vitrectomy and Lensectomy. J Clin Med. 2023;12(22):6981. doi: 10.3390/jcm12226981.
13. Russell JF, Albini TA, Berrocal AM, Dubovy SR, Rosenfeld PJ, Smiddy WE, et al. Anti-Vascular Endothelial Growth Factor Therapy for Choroidal Rupture-Associated Choroidal Neovascularization. Ophthalmol Retina. 2020;4(2):226–228. doi: 10.1016/j.oret.2019.09.008.
14. Kim M, Kim JH, Seo Y, Koh HJ, Lee SC. Intravitreal Bevacizumab for Traumatic Choroidal Rupture. Optom Vis Sci. 2015;92(10):e363–367. doi: 10.1097/OPX.0000000000000677.