

Ann. Acad. Med. Siles. (Online) 2026; DOI: 10.18794/aams/221204

Case report

A case of sarcoidosis presenting as arthritis and fever

Maria Wawrzyn¹, Wiktoria Frankowska¹, Julia Bień¹, Anna Mazur¹, Karolina Wydrych¹,
Magdalena Zych², Agata Stanek^{2,3}

¹Students' Scientific Club, Department of Internal Medicine, Metabolic Diseases and Angiology,
Faculty of Health Sciences in Katowice, Medical University of Silesia, Katowice, Poland

²Department of Internal Medicine, Metabolic Diseases, and Angiology,
Upper-Silesian Medical Centre of the Medical University of Silesia in Katowice, Poland

³Department of Internal Medicine, Metabolic Diseases and Angiology,
Faculty of Health Sciences in Katowice, Medical University of Silesia, Katowice, Poland

Address for correspondence:

lek. Magdalena Zych
Klinika Chorób Wewnętrznych, Metabolicznych i Angiologii
Górnośląskie Centrum Medyczne im. prof. Leszka Gieca ŚUM
ul. Ziołowa 45/47, 40-635 Katowice
e-mail: magnitudoa@gmail.com

Received: 03.04.2026, Revised: 06.04.2026, Accepted: 28.04.2026, Published: June 2026

This is an open access article made available under the terms of the Creative Commons Attribution-ShareAlike 4.0 International (CC BY-SA 4.0) license, which defines the rules for its use. It is allowed to copy, alter, distribute and present the work for any purpose, even commercially, provided that appropriate credit is given to the author and that the user indicates whether the publication has been modified, and when processing or creating based on the work, you must share your work under the same license as the original. The full terms of this license are available at <https://creativecommons.org/licenses/by-sa/4.0/legalcode>.

© Copyright by Author(s)

Publisher: Medical University of Silesia, Katowice, Poland

ABSTRACT

Sarcoidosis is a systemic granulomatous disease of unknown etiology, characterized by marked clinical heterogeneity and the absence of a single diagnostic test. It most commonly affects young adults, mainly women, and typically involves the lungs and hilar lymph nodes, although extrapulmonary organ involvement is frequently observed. We present the case of a 39-year-old man with obesity (body mass index 33.25 kg/m²), arterial hypertension, and newly diagnosed type 2 diabetes mellitus, who was hospitalized due to pain and swelling of the ankle joints and the right wrist persisting for three weeks. Empirical outpatient antibiotic therapy failed to improve the patient's condition. Laboratory findings revealed leukocytosis with neutrophilia, markedly elevated inflammatory markers, and metabolic abnormalities. Chest imaging demonstrated bilateral hilar and mediastinal lymphadenopathy as well as subpleural fibrotic changes in segment 9 of the right lung, raising suspicion of sarcoidosis. This case highlights the wide range of clinical manifestations of sarcoidosis, emphasising the importance of a thorough diagnostic evaluation. It highlights that sarcoidosis may present predominantly with joint involvement without typical cutaneous or respiratory manifestations. Coexisting metabolic disorders may further modify the inflammatory response and obscure the classic clinical presentation. Therefore, sarcoidosis should be considered in the differential diagnosis of arthritis of unclear etiology, particularly in patients with concomitant metabolic disturbances.

KEYWORDS

metabolic syndrome, sarcoidosis, arthritis

INTRODUCTION

Sarcoidosis is a systemic granulomatous disease of unknown etiology, predominantly affecting young adults. Globally, the prevalence of sarcoidosis is estimated to be 4.2–160/100 000, whereas in Poland, the annual incidence is 10/100 000. It most frequently manifests as hilar lymphadenopathy and pulmonary parenchymal involvement [1]. Although the lungs are the most frequently affected site, the disease can involve multiple other organs, including the liver, spleen, heart, eyes, skin and even the nervous system [2].

The pathogenesis of sarcoidosis likely involves dysregulation of lymphocyte activation pathways in response to an unidentified antigen, driven by polymorphisms within various genes [1]. While specific autoantigens or autoantibodies responsible for the disease's development have not been identified, it exhibits features reminiscent of autoimmune diseases, particularly its association

with human leukocyte antigen (HLA) genotypes, a favorable response to immunosuppressive therapy and frequent co-occurrence with other autoimmune disorders [2].

The hallmark morphological feature of sarcoidosis is the accumulation of Th1 lymphocytes and macrophages within lymph nodes and lymphatic-rich tissues. These cells subsequently transform into epithelioid cells, forming non-caseating granulomas surrounded by lymphocytes and fibroblasts [3].

In medical literature, sarcoidosis has earned a reputation as one of the greatest challenges in contemporary internal medicine diagnostics. Although most patients present with non-specific systemic symptoms, such as chronic fatigue, malaise, anorexia, or low-grade fever, the disease is characterized by significant heterogeneity [1,2]. The clinical presentation depends directly on the localization of granulomas within specific organs and can range from entirely asymptomatic forms, detected incidentally on imaging, to life-threatening manifestations [3].

Sarcoidosis can mimic a broad spectrum of conditions, ranging from cancer and infectious diseases to rare immunological disorders. Due to its polymorphism and the lack of a dedicated, specific pathognomonic test, the diagnostic process often relies on the principle of exclusion, necessitating an interdisciplinary approach [3]. This clinical unpredictability is the reason why cases of sarcoidosis with an atypical course are crucial for expanding medical knowledge regarding the pathogenesis and appropriate differential diagnosis of this disease.

This case report describes a patient with sarcoidosis who presented with swollen joints and fever, and what was the most challenging without any pulmonary manifestation, which made establishing the diagnosis much more difficult.

CASE REPORT

A 39-year-old obese male (body mass index 33.25 kg/m²) with a medical history of arterial hypertension was transferred from the Emergency Department to the Internal Medicine Ward due to persistent joint pain lasting for 3 weeks. The patient reported pain, swelling, morning stiffness, erythema, and increased local temperature of both ankle joints and the right wrist. These symptoms were accompanied by recurrent fever up to 39.5 °C. Prior outpatient treatment with amoxicillin/clavulanic acid and clarithromycin yielded no clinical improvement. The patient denied any history of tick bites or recent infections.

Physical examination revealed massive edema of the feet and ankle regions with associated tenderness and increased local warmth. Swelling and tenderness were also noted around both wrists. Additionally, abdominal obesity was observed.

Laboratory tests showed elevated inflammatory markers, including a C-reactive protein (CRP) level of 108 mg/l and leukocytosis ($10.22 \times 10^3/\mu\text{l}$) with neutrophilia ($8.04 \times 10^3/\mu\text{l}$). Other significant findings included:

- lipid profile: total cholesterol of 156 mg/dl and LDL fraction of 108 mg/dl
- coagulation and liver function: elevated D-dimer levels (7196.65 ng/ml) and increased liver enzyme activity (ALT 52 U/l, GGT 66.7 U/l)
- metabolic status: newly diagnosed type 2 diabetes (fasting glucose 195 mg/dl, HbA1c 8.28%) and fatty liver disease, the latter confirmed by a contrast-enhanced abdominal computed tomography (CT) scan showing significantly reduced hepatic tissue density.

Chest imaging was performed; an initial X-ray showed a widened right pulmonary hilum, which prompted further investigation via chest CT. The CT scan revealed enlarged subcarinal lymph nodes (up to 21 mm), hilar lymph nodes (up to 16 mm), and lymph nodes near the aortic arch (up to 16 mm), as well as subpleural fibrous changes in segment 9 of the right lung. Empiric intravenous antibiotic therapy was initiated with ceftriaxone, followed by cefotaxime after urine culture results confirmed a *Klebsiella pneumoniae* infection. Concurrent analgesic and anti-inflammatory treatment resulted in clinical improvement and the normalization of inflammatory parameters (CRP decreased to 43 mg/l).

The patient was advised to follow a low-carbohydrate and low-fat diet, pursue weight reduction, and adhere to the following medication regimen: Pantoprazole: 20 mg/day (fasting), Lercanidipine hydrochloride: 10 mg/day, Metoprolol: 100 mg/day, Etoricoxib: 60 mg/day, Metformin: 750 mg/day, Topical Diclofenac (gel): applied 3 times daily.

The patient was discharged in a good general condition. A follow-up admission to the Department of Pulmonology has been scheduled for further diagnostic evaluation, including bronchoscopy with endobronchial ultrasound (EBUS).

A bronchoscopy with EBUS was performed, visualising enlarged lymph nodes at 4R, 7 and 11L. Biopsies were taken from these nodes. The results of the histopathological examination showed no cancer cells. The diagnostic material contained lymph node cells and fragments with deposits of coal dust focally, as well as granulomatous structures composed of epithelioid histiocytes. There were no signs of necrosis. These findings corresponded to sarcoid granulomas in correlation with clinical data. The histopathological diagnosis of sarcoidosis was confirmed.

DISCUSSION

The presented case concerns a 39-year-old male patient with obesity, hypertension, type 2 diabetes, and metabolic-associated fatty liver disease. Prior to hospitalization, the patient underwent unsuccessful outpatient antibiotic therapy.

Upon admission, high fever, acute arthritis of the ankles and the right wrist, and significantly elevated inflammatory markers were observed. The lack of response to antibacterial treatment, combined with a characteristic chest CT scan-revealing bilateral hilar lymphadenopathy and subcarinal lymph node enlargement, led to the suspicion of sarcoidosis as the primary cause of the articular manifestations (Figure 1).

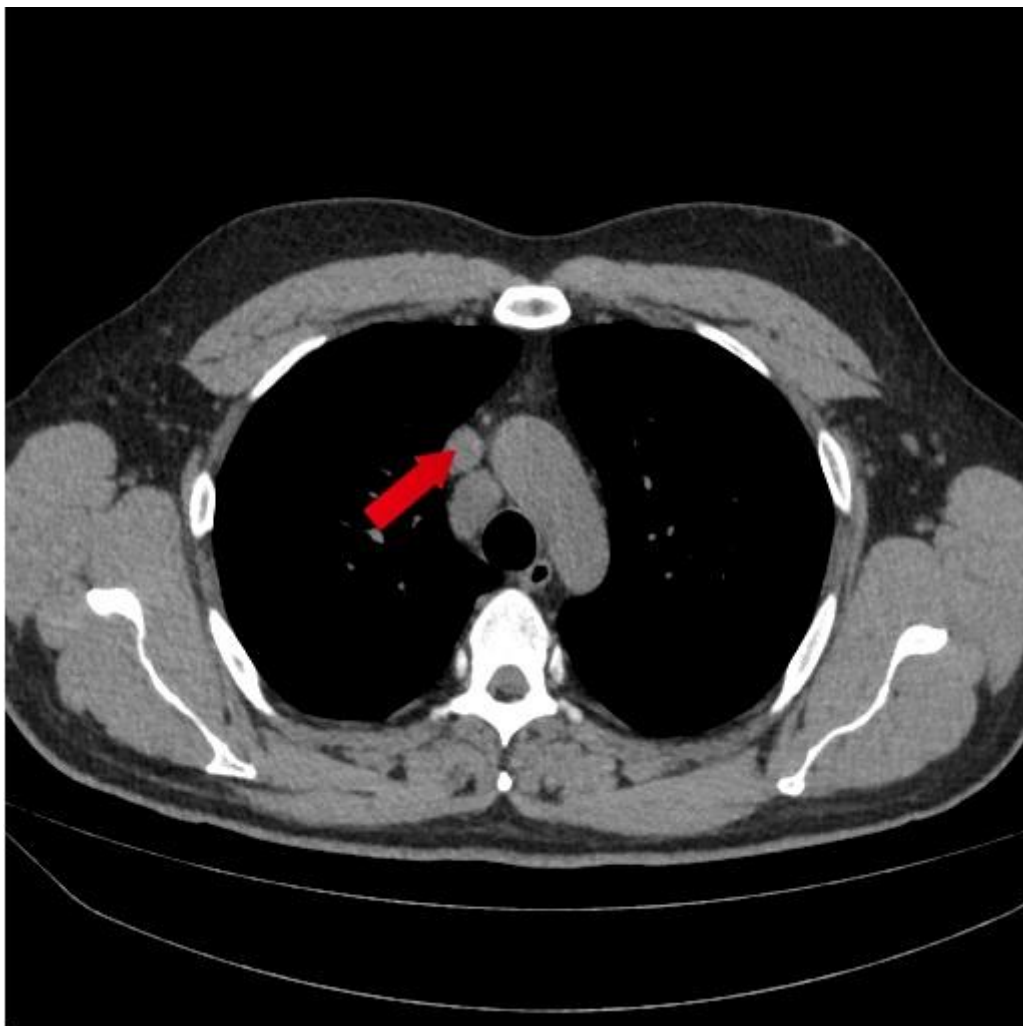


Fig. 1. The computed tomography scan of a chest – enlarged lymph node near the aortic arch

This case was distinguished by the significant severity of symptoms and the need for hospitalization. In contrast to the majority of reported cases [4], where the clinical course was milder, the symptoms in this patient persisted for many weeks. The absence of erythema nodosum and the presence of metabolic syndrome components may have modified the inflammatory profile of sarcoidosis, significantly complicating its early identification.

Despite many features constituting a typical clinical picture of sarcoidosis, such as the patient's age and respiratory involvement, the prolonged duration of articular symptoms remains a point of interest [5]. It is hypothesized that this was caused by the overlap of inflammatory states induced by type 2 diabetes, abdominal obesity, and sarcoidosis. The former two entities result in increased synthesis of pro-inflammatory cytokines, namely IL-6, IL-1 β , and TNF- α [6]. A high level of visceral adipose tissue also increases the activation of M1 macrophages. The convergence of all these factors may have led to excessive immune system stimulation, subsequently intensifying joint symptoms. Furthermore, increased body weight causes mechanical overloading, which directly impacts the intensification of musculoskeletal symptoms [7,8,9].

Another question arising from the analysis of this case concerns the lack of cutaneous manifestations, which are frequent in patients with chronic articular symptoms [5]. Medical literature describes rheumatologic sarcoidosis and its clinical presentation, noting that erythema nodosum is one of the most common complaints within this phenotype. In the presented case, the patient did not exhibit such lesions, which may have hindered the classification of the disease [10,11,12,13]. However, scientific research indicates that the occurrence of erythema nodosum is not consistently frequent in patients with joint-oriented sarcoidosis.

This suggests that the diagnosis should not be excluded despite the absence of skin lesions.

Regarding obesity, its coexistence with the discussed disease may mask symptoms; specifically, in the rheumatologic phenotype, it may lead to the non-appearance of erythema nodosum [7,8,9].

Musculoskeletal manifestations in the course of sarcoidosis pose a diagnostic challenge due to their immense heterogeneity [14]. Although the disease is primarily associated with the respiratory system, a meta-analysis involving over 8,000 patients proves that arthritis accompanies one in eight patients (12%) at the time of diagnosis [14]. The classic clinical phenotype, involving inflammation of the large joints of the lower extremities with fever and hilar lymphadenopathy, is considered the dominant pattern [14]. Nevertheless, while in most cases (approx. 74%) these symptoms resolve spontaneously within 6 weeks [4], sarcoidosis can closely mimic other rheumatologic conditions, leading clinicians down a false diagnostic path [15]. Chronic arthritis is usually a part of the multiorgan form of sarcoidosis. Arthritis occurs in a form of oligoarthritis affecting the large joints. Tenosynovitis and periarticular soft tissue mild inflammation are more frequently found than true synovitis. Tenosynovitis is localized mostly within the wrist or ankle joint, and is symmetrical [16].

In the differential diagnosis of sarcoidosis, it is crucial to consider atypical forms that mask the primary cause through an acute course. Some reports highlight cases where Löfgren syndrome clinically overlaps with other inflammatory states, leading to diagnostic difficulties [15,17]. Similar to the described patient, there are instances where only thoracic imaging revealed asymptomatic

lymphadenopathy [15,17]. Diagnostic challenges are compounded by the absence of erythema nodosum, and atypical localization of lesions (e.g., wrists) often leads to a misdirected search for other systemic causes [15]. The spectrum of challenges is further broadened by the patient's metabolic disorders; data suggest that the prevalence of diabetes in sarcoidosis is significantly higher compared to healthy control groups [18].

In laboratory investigations, the concentration of D-dimers was measured, a parameter commonly used to exclude certain cardiovascular diseases. Their levels may also increase in the presence of chronic inflammation. In the presented patient, the D-dimer level was 7196.65 ng/mL, which exceeds the upper limit of normal by more than fourteenfold. Such a markedly elevated result may complicate the selection of an appropriate diagnostic strategy, potentially adversely affecting subsequent patient management.

This situation highlights the issue of excessive and insufficiently judicious ordering of this laboratory test [19]. Treatment of patients with this clinical entity focuses primarily on the observation and control of chronic arthritis and the prevention of permanent functional impairment. In mild forms, non-steroidal anti-inflammatory drugs are used, whereas systemic glucocorticoids (e.g., Prednisone) in low to moderate doses form the mainstay of therapy for persistent disease activity. In cases of a chronic course or the need for steroid-sparing therapy, disease-modifying antirheumatic drugs, most commonly methotrexate or hydroxychloroquine, are recommended. In patients refractory to conventional treatment, biological therapy with TNF- α inhibitors, such as infliximab or adalimumab, may be considered [20].

The discussed patient history effectively illustrates how comorbidities can mask or exacerbate certain symptoms of the presented entity. Therefore, when sarcoidosis is suspected, a thorough diagnostic workup should be performed to ensure no significant symptoms suggesting the disease are overlooked.

CONCLUSIONS

Sarcoidosis should be considered in the differential diagnosis of acute inflammatory arthritis, particularly when symptoms are refractory to antibiotic therapy and accompanied by systemic inflammation. Atypical presentations lacking pulmonary or cutaneous manifestations may delay diagnosis, especially in patients with coexisting metabolic disorders.

Given the increasing prevalence of obesity, special attention should be paid to atypical manifestations of sarcoidosis in obese patients, as the disease may follow a course distinct from that classically described. Early recognition and comprehensive evaluation, including chest imaging and histological confirmation, are essential to ensure appropriate management.

Use of AI tools statement

Gemini 3.1 Pro was used for article translation.

Authors' contribution

Study design – W. Frankowska, A. Mazur, J. Bień, K. Wydrych, M. Wawrzyn

Data collection – M. Wawrzyn, J. Bień, K. Wydrych, A. Mazur, W. Frankowska

Manuscript preparation – J. Bień, K. Wydrych, M. Wawrzyn, A. Mazur, W. Frankowska, A. Stanek, M. Zych

Literature research – A. Mazur, W. Frankowska, K. Wydrych, M. Wawrzyn, J. Bień

Final approval of the version to be published – K. Wydrych, W. Frankowska, A. Mazur, J. Bień, M. Wawrzyn, A. Stanek, M. Zych

REFERENCES

1. Piotrowski W, Rowińska-Zakrzewska E, Bestry I. Sarkoidoza. In: Gajewski P [ed.]. Interna Szczeklika 2024. Medycyna Praktyczna. Kraków 2024, p. 807–812.
2. Xu D, Tao X, Fan Y, Teng Y. Sarcoidosis: molecular mechanisms and therapeutic strategies. *Mol Biomed.* 2025;6(1):6. doi: 10.1186/s43556-025-00244-z.
3. Cooper D, Suau S. Sarcoidosis. *Emerg Med Clin North Am.* 2022;40(1):149–157. doi: 10.1016/j.emc.2021.08.012.
4. Ungprasert P, Crowson CS, Matteson EL. Clinical characteristics of sarcoid arthropathy: A population-based study. *Arthritis Care Res.* 2016;68(5):695–699. doi: 10.1002/acr.22737.
5. Zdrojewski Z, Wierzba K. Sarcoidosis – multisystem disorder. [Article in Polish]. *Forum Reumatol.* 2018;4(4):225–230. doi: 10.5603/FR.2018.0011.
6. Czupryniak L. Beta-protekcja – patofizjologiczny element terapii cukrzycy typu 2. *Diabetol Prakt.* 2007;8(suppl. B):B11–B15.
7. Cozier YC, Govender P, Berman JS. Obesity and sarcoidosis: consequence or contributor? *Curr Opin Pulm Med.* 2018;24(5):487–494. doi: 10.1097/MCP.0000000000000503.
8. Kobak S, Semiz H, Akyildiz M, Gokduman A, Atabay T, Vural H. Serum adipokine levels in patients with sarcoidosis. *Clin Rheumatol.* 2020;39(7):2121–2125. doi: 10.1007/s10067-020-04980-1.
9. Cozier YC, Coogan PF, Govender P, Berman JS, Palmer JR, Rosenberg L. Obesity and Weight Gain in Relation to Incidence of Sarcoidosis in US Black Women: Data From the Black Women's Health Study. *Chest.* 2015;147(4):1086–1093. doi: 10.1378/chest.14-1099.
10. Poole GW. The diagnosis of sarcoidosis. *Br Med J.* 1982;285(6338):321–322. doi: 10.1136/bmj.285.6338.321.

- 11.** Kobak S, Sever F, Usluer O, Goksel T, Orman M. The clinical characteristics of sarcoid arthropathy based on a prospective cohort study. *Ther Adv Musculoskelet Dis.* 2016;8(6):220–224. doi: 10.1177/1759720X16670598.
- 12.** Ekin A, Misirci S, Sertkaya O, Coskun BN, Yagiz B, Dalkilic E, et al. Rheumatologic perspectives on sarcoidosis: predicting sarcoidosis-associated arthritis through comprehensive clinical and laboratory assessment. *J Clin Med.* 2024;13(24):7563. doi: 10.3390/jcm13247563.
- 13.** Kobak S. Sarcoidosis: a rheumatologist's perspective. *Ther Adv Musculoskelet Dis.* 2015;7(5) 196–205. doi: 10.1177/1759720X15591310.
- 14.** Yeung T, Grebowicz A, Nevskaya T, Zahid S, Pope JE. Joint involvement in sarcoidosis: systematic review and meta-analysis of prevalence, clinical pattern and outcome. *Rheumatology.* 2024;63(7):1803–1814. doi: 10.1093/rheumatology/keae048.
- 15.** Dey R, Kattamuri L, Chirrareddy Y, Luna Ceron E, Sharma K, Padilla O, et al. Löfgren's syndrome: A unique presentation of sarcoidosis masquerading as lower extremity cellulitis. *J Investig Med High Impact Case Rep.* 2025;13:23247096251352366. doi: 10.1177/23247096251352366.
- 16.** Kucharz EJ. Osseous manifestations of sarcoidosis. *Reumatologia.* 2020;58(2):93–100. doi: 10.5114/reum.2020.95363.
- 17.** Ogami R, Otsuka Y, Hasegawa K, Tokumasu K, Obika M, Fujii M, et al. Acute arthritis caused by sarcoidosis. *J Gen Fam Med.* 2023;24(4):264–265. doi: 10.1002/jgf2.621.
- 18.** Benmelouka AY, Abdelaal A, Mohamed ASE, Shamseldin LS, Zaki MM, Elsaedy KS, et al. Association between sarcoidosis and diabetes mellitus: a systematic review and meta-analysis. *Expert Rev Respir Med.* 2021;15(12):1589–1595. doi: 10.1080/17476348.2021.1932471.
- 19.** Chojnowski K. D-dimer - diagnostic and prognostic marker of venous thromboembolism. *Hematol Clin Pract.* 2010;1(2):102–108.
- 20.** Piotrowski WJ, Bączek K, Majewski S. Zasady leczenia sarkoidozy na podstawie wytycznych European Respiratory Society (ERS) i stanowiska British Thoracic Society (BTS). *Pneum Pol.* 2022;3(1–2):14–22.