

## Is Patent Foramen Ovale a cause of stroke?

### Przetrzywały otwór owalny przyczyną udaru mózgu?

Grażyna Markiewicz-Łoskot<sup>1</sup>, Joanna Jaromin<sup>2</sup>

<sup>1</sup> Department of Pediatric Cardiology, School of Medicine in Katowice, Medical University of Silesia, Katowice, Poland

<sup>2</sup> Department of Nursing and Social Medical Problems, School of Health Sciences in Katowice, Medical University of Silesia, Katowice, Poland

#### ABSTRACT

**INTRODUCTION:** Cardio-vascular anomalies, including patent foramen ovale, are the cause of 40% of cryptogenic strokes. Patent foramen ovale is a heart malformation which does not show clinical symptoms. It is recognisable in young patients with stroke (younger than 55 years old), if there is no other cause of stroke.

**AIM:** The purpose of the study was to assess the incidence of patent foramen ovale in a group of young patients suffering a stroke before 55 years of age with migraine headaches.

**METHODS:** The research included 50 stroke patients younger than 55 (average age of 48, 21 females, 29 males). The patients were treated from 1 January 2012 to 31 December 2012 in the Stroke Unit of the Neurological Ward. The medical histories were analysed and the data including sex, age, the symptoms during admission to the ward, the results of the diagnostic tests that were performed and the applied therapy.

**RESULTS:** In the study group of young, stroke patients before 55 years of age, patent foramen ovale was recognized in 16% of the patients. The PFO incidence was especially high (83%) in young stroke patients with migraine headaches, representing 12% of the whole study group.

**CONCLUSIONS:** The frequent occurrence of patent foramen ovale should lead to taking appropriate prophylactic measures using diagnostic echocardiography, especially in patients with migraine headaches and for example in balance tests for the young.

#### KEY WORDS

patent foramen ovale, stroke, migraine headache, prevention

#### STRESZCZENIE

**WSTĘP:** Anomalie sercowo-naczyniowe, w tym przetrzywały otwór owalny, są przyczyną 40% udarów kryptogennych. Przetrzywały otwór owalny jest wadą serca, które zwykle nie daje objawów klinicznych. Jest rozpoznawalny u młodych udarowych pacjentów (przed 55 rokiem życia – r.ż.) przy braku innych przyczyn udaru mózgu. Celem pracy była ocena częstości występowania przetrzywałego otworu owalnego w grupie młodych pacjentów z udarem przed 55 r.ż. z migrenowymi bólami głowy.

Received: 21.01.2014

Revised: 09.05.2014

Accepted: 12.06.2014

Published online: 24.03.2015

**Address for correspondence:** dr hab. n. med. Grażyna Markiewicz-Łoskot, Zakład Pielęgniarstwa i Społecznych Problemów Medycznych Wydziału Nauk o Zdrowiu Śląskiego Uniwersytetu Medycznego w Katowicach, ul. Medyków 16, 40-752 Katowice, tel. + 48 32 208 86 45, e-mail: jaromin.joanna@o2.pl

Copyright © Śląski Uniwersytet Medyczny w Katowicach  
www.annales.sum.edu.pl

**MATERIAŁ I METODY:** Badaniami objęto 50 młodych, udarowych pacjentów przed 55 r.ż. (średnia wieku 48, ♀: 21, ♂: 29). Pacjenci byli hospitalizowani w okresie od 1 stycznia 2012 do 31 grudnia 2012 roku w pododdziale udarowym na oddziale neurologicznym. Analizowano historie chorób, uzyskując dane odnośnie do płci, wieku, objawów przy przyjęciu, wyników przeprowadzonych badań diagnostycznych oraz zastosowanej terapii.

**WYNIKI:** W badanej grupie młodych udarowych pacjentów (przed 55 r.ż.) przetrwały otwór owalny był stwierdzony u 16% pacjentów. Częstość występowania PFO była szczególnie wysoka (83%) w grupie młodych udarowych pacjentów z migrenowymi bólami głowy, stanowiącej 12% całej grupy badanej.

**WNIOSKI:** Częste występowanie przetrwałego otworu owalnego, jako jedynej zidentyfikowanej przyczyny udaru mózgu u młodych pacjentów przed 55 r.ż., skłania do podjęcia odpowiednich działań profilaktycznych z diagnostyką echokardiograficzną, szczególnie u osób z migrenowymi bólami głowy i np. w czasie badań bilansowych u młodzieży.

## SŁOWA KLUCZOWE

Przetrwały otwór owalny, udar mózgu, migrena, ból głowy

## INTRODUCTION

Cardio-vascular anomalies, including patent foramen ovale, are the cause of 40% of cryptogenic strokes. Patent foramen ovale is a primary, acyanotic leakage heart malformation, which does not show clinical symptoms. It is recognisable in young patients who have undergone a stroke (younger than 55 years old), if there is no other cause of stroke [1]. PFO is defined as an incomplete fusion of an oval bottom flabby valve with the atrial septum seam [10].

In most cases, a PFO will remain asymptomatic for life. Patent foramen ovale as an anatomic entity was first described in 1564 by Leonardi Botallo, an Italian surgeon working at the French royal court [2]. However, since the initial link of a fatal stroke in a young woman with PFO in Cohnheim in 1877, PFO has been increasingly recognized as a potential mediator of systemic embolism [3].

The role of patent foramen ovale as a potential cause of stroke has been a subject of increasing controversy since 1988. That year, the first of many case-control studies that described an increased prevalence of PFO in patients with cryptogenic stroke were conducted [4].

According to the research conducted by the American College of Cardiology Foundation in 2010, the occurrence of PFO in the world is estimated at 20% to 35% of the population (which means that one person in five has the heart malformation) [5] and its appearance decreases with age. The prevalence of PFO has been described as similar across different race-ethnic groups [6].

Physiologically, patent foramen ovale occurs in fetal life and is located in the septum. It is a channel allowing maternally oxygenated venous blood to pass from the right atrium to the left one, thus bypassing pulmonary circulation [4]. Closure takes place just after birth and it should close completely within the first year of life. Patent foramen ovate (PFO) is a connection between the right and left atria that is present in approximately 25% of the adult population [7] with a similar prevalence in both sexes [8].

How then does PFO contribute to stroke?

Now, when in the right atrium there is some embolic material (a thrombus or air- in decompression accidents [8]), it may get through the foramen ovale into the left atrium. Then under the influence of atrial contraction it moves to the left ventricle and later the embolic material goes to the aortic arch, where it enters the common carotid artery causing cerebral stroke. The most common pathogenesis of stroke in this case is based on the occurrence of a paradoxical embolism to the central nervous system [9] and is associated with migraine, vascular headache and platypnea-orthodeoxia syndrome [8].

Risk factors of the first and further strokes in patients with PFO:

- Age < 55 years
- Recurrent ischemic events
- multiple ischemic lesions in brain imaging studies
- stroke associated with the attempt of Valsalva
- large foramen ovale
- a large right-to-left leakage in TEE study during provocation tests
- concomitant septal aneurysm (ASA) [20].

Increasingly, the scientific literature discusses the relationship between the existence of patent foramen ovale and the occurrence of a migraine attack. The existence of PFO is much more common in patients with migraine with aura. Such a relationship is not observed in patients with migraines without aura [11]. Patent foramen ovale (PFO) is more common in patients who are diagnosed having migraine with aura than in the general population. PFO is present in about 40% to 60% of people who have migraine with aura compared with 20% to 30% of the general population [20]. According to the latest scientific findings, in one study active patent foramen ovale was found in 48% of patients suffering from migraine with aura and 23% of patients with migraine without aura [21]. However, in another study, the existence of a PFO was found in 53% of patients with migraine with aura and in 25% of patients with migraine without aura and patients in the control group [23]. PFO may be the cause of migraine with aura when a paradoxical embolism goes through the PFO, triggering a transient ischemic attack and focal neurological signs as well as symp-

toms of migraine aura occur [22]. It was observed, however, that for some patients with migraine, PFO does not increase the risk of clinically silent lesions of white brain matter damage [24].

## DIAGNOSTICS AND TREATMENT

In young patients with ischemic stroke, there is a need to broaden the scope of diagnostic tests because of a greater likelihood of non-atherosclerotic reasons [21]. So who should be targeted for diagnosis to detect PFO?

- persons < 65 years of age,
- patients with a history of cerebral infarction or cerebral ischemic event,
- patients with migraine (especially with aura),
- patients with vascular damage to the brain, confirmed by imaging studies (CT, MRI head), without risk factors for embolic-thrombophlebitis (hypertension, diabetes, atrial fibrillation) [20].

The most important diagnostic test for the detection of PFO is transthoracic echocardiography used in children and transesophageal echocardiography used in adults. PFOs with active right-to-left shunts can be detected with transesophageal echocardiography (TEE), transthoracic echocardiography (TTE), or transcranial Doppler ultrasound (TCD). PFOs are detected by TEE in three ways: colour flow Doppler detects abnormal flow across the PFO; omniplane transducers permit direct B-mode visualization of the separation of the septum primum and septum secundum; and functional evidence of a PFO is provided by early passage of injected, aerated isotonic saline microbubbles from the right-to-left atrial chambers.

In the first phase the construction of the atrium septum is assessed. Then the antecubital vein administration of a "contrast", prepared immediately before use by mixing 9 ml of 0.9% NaCl with 1 ml of air between two syringes. Each patient does a Valsalva maneuver before contrast administration to assess his ability to properly implement it. Going The passage of contrast is evaluated before, during and after the Valsalva maneuver [20]. The Valsalva maneuver (VM) involves making a forced expiration against a closed glottis. During VM, the pressure in the chest increases, causing numerous hemodynamic changes and initiating multiple impulses from the autonomic nervous system. This maneuver was used for the first time by the Italian anatomist Antonio Valsalva to open and unblock the Eustachian tube in patients with blocked drainage from the middle ear (e.g. due to inflammation). The Valsalva maneuver is physiologically performed during static efforts for example, when lifting heavy weights, straining in childbirth, defecation or blowing on musical instruments [20].

The test result is described using a scale of 0–3, where 0 means no passage of contrast bubbles to the left atrium, 1 – a few bubbles of contrast pass, 3 – passage of clouds of bubbles, while 2 is an intermediate value between 1 and 3. Patients with a positive TEE test result demonstrating the existence of a right–left shunting of blood when assessing the indications are sent for percutaneous ASD closure.

TEE has the sensitivity of 89% and specificity of 100% in detecting PFOs compared with autopsy diagnosis and remains the preferred test if tolerated by patients because it allows for direct visualization of the PFO and exploration of additional atrial and aortic emboli sources such as ASA (atrial septal aneurysm) and aortic arch atherosclerosis [10].

Transcranial Doppler ultrasonography (TCD) is a test performed in the Doppler laboratory. One of the veins of the forearm is punctured in order to set venipuncture. Contrast is conducted immediately before testing. 9 ml formed by mixing saline and 1 ml of air in two syringes are connected by a tap. The test is performed in the supine position with the patient on his back [20].

Using 2 MHz probes applied to the surface of the skull in the vicinity of the temporal lobes, flow is monitored in the cerebral arteries – most commonly the middle cerebral arteries. After obtaining the blood flow in the selected vessel using special software, the registration embolic signals proceeds. A bolus injection contrast (shaken saline) is given by intravenous line, and then the patient is asked to perform the Valsalva maneuver and the number of embolism signals during rest and for about two minutes after the Valsalva maneuver is observed [20].

The test result can be positive – a current signals a cerebral embolism, or negative – no signs of cerebral embolism. In the event of a questionable test result the test is repeated. Patients with a positive test result c–TCD proving the existence of a right–left shunting of blood, are sent for further cardiological diagnostics [25].

Currently, there are no clear standards of behavior in patients with PFO after ischemic stroke.

The treatment, which reduces the risk of another stroke, involves the administration of antiplatelet agents, oral anticoagulants (conservative treatment) and by operational closure of the PFO.

The treatment offered to patients with PFO depends on the symptoms that accompany them (e.g. migraine headaches), and from a history of ischemic events in an interview.

The treatment options include conservative treatment with an antiplatelet and anticoagulant.

Antiplatelet and anticoagulant therapy are used to reduce the formation of blood clots and venous embolization when closing septal defects, surgically or by an endovascular device that is designed to eliminate

embolic particles that could enter the arterial system [2].

Patients diagnosed with other structural heart defects who had experienced an ischemic event or there is lack of consent of the patient for anticoagulant therapy, are proposed operations are proposed: surgical and percutaneous PFO closure, which is a safe and effective method [26].

Percutaneous PFO closure has replaced surgical closure and constitutes an alternative treatment. This eliminates the path to a paradoxical embolism and can therefore bypass the need for long-term anticoagulant therapy. It is worth noting that it is associated with a low periprocedural risk, but a significant expense [3].

The indications currently approved for percutaneous closure are recurrent strokes, the orthodeoxia syndrome and decompression sickness in divers [6].

For percutaneous coronary intervention, according to the latest reports, clasps are used: CardioSeal, Amplatzer septal STARFLEX or an occluder. Implantation is done under fluoroscopy and transesophageal or intracardiac echocardiography.

## MATERIALS AND METHODOLOGY

The research included 50 stroke patients younger than 55 (average age of 48, ♀: 21, ♂: 29). The patients were treated from 1<sup>st</sup> January 2012 to 31<sup>st</sup> December 2012 in the Stroke Unit of the Neurological Ward. The medical histories were analysed and the data including sex, age, the symptoms during admission to the ward,

the results of the diagnostic tests that were performed and the applied therapy.

On the basis of the collected data and consultations with the medical team, a summary of clinical observations, a clinical observation of a test group with PFO and one without PFO were formed.

For the whole study group, such inclusion and exclusion criteria apply.

The inclusion criteria for the study group was:

- Age < 55 years
- Hospitalization in the Stroke Unit of the Neurological Ward
- Clinical signs of stroke (hemiparesis/hemiplegia, sudden numbness and weakness of the muscles of the face and extremities, speech disturbances of a type of aphasia, blurred vision, headache, nausea and vomiting)
- Hemorrhagic stroke excluded in the examination with computed tomography (CT)
- Specialized examination conducted: ultrasound Doppler, transthoracic echocardiography (TTE) and transesophageal (TEE)

The exclusion criteria for the study group:

- Age > 55 years
- No clinical signs of stroke
- Hemorrhagic stroke in the examination with computed tomography (CT)
- Lack of specialized examination: ultrasound Doppler transthoracic, echocardiography (TTE) or transesophageal (TEE)

## RESULTS

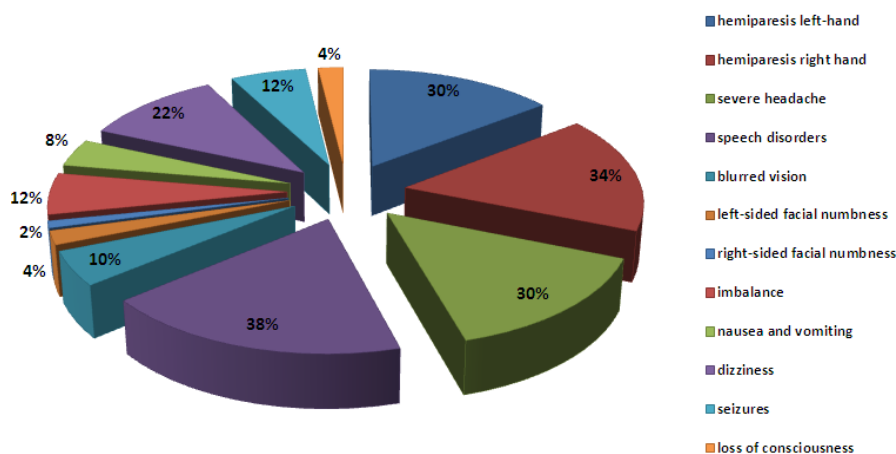
The study included 50 patients, including 21 women (42%) and 29 men (58%) Tables I, II.

**Table I.** Clinical observation test group with PFO and without PFO  
**Tabela I.** Obserwacja kliniczna badanej grupy z PFO i bez PFO

	Total Cohort (n = 50)	PFO-Positive (n = 8)	PFO-Negative (n = 42)
Age (median)	47.1	45.2	47.5
Occurrence of at least a second stroke	10 (20%)	0	10 (23.8%)
Sex			
Female	21 (42%)	5 (62.5%)	16 (38%)
Male	29 (58%)	3 (37.5%)	26 (62%)
Hypertension	20 (40%)	1 (12.5%)	19 (45.2%)
Migraine headaches with visual aura	6 (12%)	5 (62.5%)	1 (4.2%)
Atherosclerosis	7 (14%)	0	7 (16.6%)
Diabetes	4 (8%)	0	4 (9.5%)
Epilepsy	6 (12%)	0	6 (14.2%)
Addictions (alcoholism, smoking)	9 (18%)	0	9 (21.4%)
Contraceptives	3 (6%)	1 (12.5%)	2 (4.7%)

**Table II.** Summary of clinical observations  
**Tabela II.** Zbiorczy arkusz klinicznej obserwacji

Research	Patients with PFO	Patients with other causes of cryptogenic stroke
Interview	no deviation from norm	family responsibilities, addictions
Neurological examination	strong headache, migraine, slight weakness, without aphasia most common hemiparesis, aphasia	
Research laboratory	correct	incorrect
EKG; Holter	correct record	abnormal in 20%
RTG thorax	correct	incorrect
TTE, TEE, with contrast- diagnostic with PFO	current leakage	lack of leakage
USG Doppler	current leakage	lack of leakage



**Fig. 1.** Percentage distribution of symptoms reported at time of admission.  
**Ryc. 1.** Rozkład procentowy objawów zgłaszanych w chwili przyjęcia

While analyzing the nature of the symptoms associated during admission to the ward, it was found that the largest group of symptoms were slurred speech, present in 38% of patients of this group while right-sided facial numbness occurred the least frequently, in only 2% of patients, Fig. 1.

In the group, 10 patients (20%) had ischemic stroke for the second time. In these patients there was a patent foramen ovale.

During hospitalization, all the patients of the study group performed both transthoracic echocardiography (TTE) and transesophageal echocardiography (TEE), which confirmed the existence of patent foramen ovale in 8 patients (16%).

6 patients (12%) at the time of admission reported symptoms of migraine with aura. In the group of patients with migraine headache, in 5 patients (83%) a patent foramen ovale during hospitalization was diagnosed.

## DISCUSSION

Patent foramen ovale (PFO) is often the only diagnosed cause of cryptogenic stroke in young patients under 55 years of age [12,13].

The literature reports that in the group of 264 patients at the age of 55 years or less after cryptogenic stroke, PFO was found in 17% of patients [12]. In a similar age group of 394 young patients with cryptogenic stroke, PFO was discovered in as many as 45% of the whole study group by means of standard diagnostic techniques [13]. In my research PFO was present in 16% of the patients in the study group.

According to current standards, secondary prevention of cerebrovascular events – consists in the closure of patent foramen ovale (PFO) only after a second cryptogenic stroke despite drug treatment (anticoagu-

lant and antiplatelet) [6]. The recurrence of acute ischemic cerebrovascular syndrome is an indication for the closure of patent foramen ovale, and the effects of treatment on the basis of multi-center clinical trials are satisfactory and prevent a further stroke [14]. Potential benefits of PFO closure is questionable.

Proponents suggest that the mechanical closure of persistent foramen ovale (PFO) is the best method of preventing the recurrence of stroke [18]. The likelihood of stroke recurrence after percutaneous closure of patent foramen oval (PFO) after 4 years is 7.8% and the literature reports the incidence of recurrent events was lower (0.5% per year) in patients after the closure of PFO than in medically treated patients (2.9% per year) [11]. The low recurrence rate of stroke after percutaneous placement of fasteners suggests greater benefits from the closure of patent foramen ovale compared with conservative treatment [15]. The opponents of the operational closure of patent foramen ovale suggest that optimal protection against recurrent stroke is antiplatelet therapy [16, 19]. According to the Guidelines of the Expert Group of the Section of Vascular Diseases of the Polish Neurological Society, there is no data enabling the making of recommendations concerning the indications for PFO closure in patients after stroke [19].

The U.S. Food and Drug Administration (FDA) indicates the possibility of serious complications after the percutaneous closure of PFO (air embolism, tension pneumothorax, retroperitoneal bleeding, embolization of the occluder or atrial perforation), which has been observed in approximately 1% of patients [6].

However, the results of recent randomized trials have shown that percutaneous PFO closure for secondary prevention of cryptogenic stroke does not result in a significant reduction in the risk of recurrent ischemic events or embolic events compared with conservative treatment [27,28,29,30].

The presence of PFO in divers may increase the risk of decompression sickness (DCS). According to Hryniewicz-Szymanska et al, the presence of PFO in this group increases the risk of severe symptoms of

decompression sickness [17]. People diving with PFO have a 4.5 times greater risk of decompression sickness and a two-fold higher risk of ischemic stroke compared with divers without a patent foramen ovale. In divers with PFO after a cerebral incident, it is recommended to discontinue diving [17], because the moment you try to dive corresponds to the mechanism of Valsalva, which may produce a paradoxical embolism and lead to stroke [18].

Given such a high incidence of PFO, as the only identified cause of stroke in young patients under 55 years of age, doctors should take appropriate preventive measures of diagnostic echocardiography, especially in patients with migraine headaches and for example in balance tests in the young.

## CONCLUSIONS

In the study group of young stroke patients before 55 years of age, patent foramen ovale was recognized in 16% of the patients. PFO incidence was especially high (83%) in young, stroke patients with a migraine headache, representing 12% of the whole study group. The frequent occurrence of patent foramen ovale should lead to taking appropriate prophylactic measures with diagnostic echocardiography, especially in patients with migraine headaches and for example in balance tests for the young.

## CONFLICT OF INTEREST

The authors have no conflicts of interest.

## ACKNOWLEDGEMENTS

None declared.

### Author's contribution

Study design – G. Markiewicz-Łoskot, J. Jaromin

Data collection – J. Jaromin

Data interpretation – G. Markiewicz-Łoskot, J. Jaromin

Manuscript preparation – J. Jaromin

Literature search – J. Jaromin

## REFERENCES

1. Mesa D., Ruiz M., Delgado M. et al. Prevalence of Patent Foramen Ovale Determined by Transesophageal Echocardiography in Patients With Cryptogenic Stroke Aged 55 Years or Older. Same as Younger Patients? *Rev. Esp. Cardiol.* 2010; 63: 315–322.
2. Thaler D., Saver J. Cryptogenic stroke and patent foramen ovale. *Curr. Opin. Cardiol.* 2008 Nov; 23: 537–544.
3. Meier B., Frank B., Wahl A. et al. Secondary stroke prevention: patent foramen ovale, aortic plaque, and carotid stenosis. *Eur. Heart J.* 2012; 33: 705–713.
4. Carpenter D., Ford A., Lee J. Patent Foramen Ovale and Stroke: Should PFOs Be Closed in Otherwise Cryptogenic Stroke? *Curr. Atheroscler. Rep.* 2010; 12: 251–258.

5. American College of Cardiology Foundation. Diagnosing Patent Foramen Ovale. <http://imaging.onlinejacc.org/article.aspx?articleid=1109583&issueno=4>. Assessed April 4, 2010.
6. Homma Sh., Tullio M. Patent foramen ovale and stroke. *J. Cardiol.* 2010; 56: 134–141.
7. DeSimone Ch., DeSimone D., Patel N. et al. Implantable cardiac devices with patent foramen ovale—a risk factor for cardioembolic stroke? *J. Interv. Card. Electrophysiol.* 2012; 35: 159–162.
8. Ferrer A., Fernandez A., Sagrera M. et al. Patent Foramen Ovale and Mechanical Ventilation. *Rev. Esp. Cardiol.* 2010; 63: 869–878.
9. Świętkiewicz I., Chojnicki M., Grzešk E. et al. Kwalifikacja dorosłych pacjentów do przeszskórnego zamknięcia ubytków w przegrodzie międzyprzedsionkowej. *Fol. Cardiol. Exc.* 2009; 4(6): 317–329.
10. Khan A. Przetrzywały otwór owalny z przemijającym atakiem niedokrwinnym. W: *Przypadki kliniczne. Wady wrodzone serca u dorosłych.* Wyd. Elsevier Urban & Partner; Wrocław 2011; tom 1: s. 14–17.
11. Stępień A. Migrena. W: *Bóle głowy. Patofizjologia. Diagnostyka. Leczenie.* Red. Stępień A. Wydawnictwo Medical Tribune Polska. Warszawa 2010; 63–137.
12. Lee T., Hsu W., Chen C., Chen S. Etiologic study of young ischemic stroke in Taiwan. *Stroke* 2002; 33: 1950–1955.
13. Rasura M., Spalloni A., Ferrari M. i wsp. A case series of young stroke in Rome. *Eur. J. Neurol.* 2006; 13: 146–152.
14. Polewczyc A., Dudek-Górska A., Błaszczyc B. et al. Udar mózgu u 19-letniego mężczyzny nadużywającego alkoholu i stosującego narkotyki. *Kardiol. Pol.* 2010; 68, 11: 1269–1271.
15. Kent D., Thaler D. et al. Is Patent Foramen Ovale a Modifiable Risk Factor for Stroke Recurrence? *American Heart Association: Stroke* 2010; 41: S26–S30.
16. Anzola G., Giusti Del Giardino, Piras M. Patent foramen ovale (PFO) and cryptogenic stroke. *J. Thromb. Haem.* 2010; 8: 1675–1677.
17. Szymański P. Drożny otwór owalny u nurka – głos w dyskusji. *Kardiol. Pol.* 2012; 70: 323–324.
18. Hryniewicz-Szymańska A., Kuch M., Braksator W. et al. Udar mózgu u młodego nurka – dyskusji ciąg dalszy. *Kardiol. Pol.* 2012; 70: 325–326.
19. Wytyczne Grupy Ekspertów Sekcji Chorób Naczyniowych Polskiego Towarzystwa Neurologicznego. Postępowanie w udarze mózgu. *Neurol. Neurochir. Pol.* 2012; 46 (1, supl. 1).
20. Kwalifikacja kardiologiczna. Migrena a PFO (przetrzywały otwór owalny). <http://www.pfo.edu.pl/migrena-a-pfo-przetrzywaly-otwor-owalny.html>. Marzec, 2014.
21. Domitrz I., Mieszkowski J., Kwieceński H. Występowanie drożnego otworu owalnego u pacjentów z migreną. *Neur. Neurochir. Pol.* 2004; 38, 2: 89–92.
22. Anzola G.P., Magoni M., Guindani M., Rozzini L., Dalla Volta G. Potential source of cerebral embolism in migraine with aura. *Neurology* 1999; 52: 1622–1625.
23. Sztajzel R., Genoud D., Roth S., Mermillod B., Le Floch-Pochr J. Patent Foramen Ovale, a Possible Cause of Symptomatic Migraine: A Study of 74 Patients with Acute Ischemic Stroke. *Cerebrovasc. Dis.* 2002; 13: 102–106.
24. Schoenen J., Magis D., Fumal A., Bolla M., Gerard P., Damas F. Prevalence of patent foramen ovale and MRI white matter lesions in migraine with aura. *Cephalalgia* 2007; 27: 578.
25. Hainsworth R. Physiology of the cardiac autonomic system. W: Malik M. red. *Clinical guide to cardiac autonomic tests.* Kluwer Academic Publishers, Londyn 1998; 3–28.
26. Homma S., Di Tullio M.R., Sacco R.L. i wsp. Surgical closure of patent foramen ovale in cryptogenic stroke patients. *Stroke* 1997; 28: 2376–2381.
27. Meier B., Kalesan B., Mattle H.P. et al. Percutaneous closure of patent foramen ovale in cryptogenic embolism. *N. Engl. J. Med.* 2013; 368: 1083–1091.
28. Carroll J.D., Saver J.L., Thaler D.E. et al. Closure of patent foramen ovale versus medical therapy after cryptogenic stroke. *N. Engl. J. Med.* 2013; 368: 1092–1100.
29. Furlan A.J., MD, Jauss M. et al. Patent Foramen Ovale and Cryptogenic Stroke. *American Heart Association. Stroke* 2013; 44: 2676–2678.
30. Freund M.A., Reeder G.S., Cabalka A.K., Cetta F., Hagler D.J. Letters to the editor. Percutaneous Device Closure of Patent Foramen Ovale for Cryptogenic Strokes/Transient Ischemic Attacks. *JACC: Cardiovasc. Interv.* 2012; 5(11): 1189.